

Protemp™ 4

Temporisation Material



Clinical case studies from around the world

3M™ ESPE™ Protemp™ 4 Temporisation Material is the first bis-acrylic material to include a new generation of sophisticated fillers that offers unparalleled strength and aesthetics. In vitro tests prove Protemp 4 material has unmatched fracture and outstanding mechanical and compressive strength, making it suitable for long-term temporisation. Indicated for single- and multiple-unit temporaries, Protemp 4 temporisation material produces a smooth, glossy surface from the beginning – eliminating the need for polishing or glaze. With tangibly less inhibition layer compared to common bis-acrylic materials, Protemp 4 temporisation material offers easy handling and a faster procedure.

3M ESPE

Clinical case 1:

Maxillary arch restorations

Clinical case by Dr. Carlos Sabrosa, Rio de Janeiro, Brazil

Initial situation: 42 year-old female patient presented with teeth UR6, UR7, UR8, UL5, UL6 and UL8 missing in the maxillary arch, and teeth LL5, LL8, LR5 and LR8 missing in the mandibular arch. Insufficient composite restorations in the anterior maxillary teeth, and insufficient amalgam restorations on existing maxillary premolars.

Treatment plan: After consultation with the patient, a decision was made to place implants in all missing maxillary teeth except teeth UR8 and UL8. Final restoration planned with all-ceramic single Lava™ Zirconia Crowns on implants and natural teeth in maxilla and in posterior teeth in mandible. No treatment on lower anteriors.

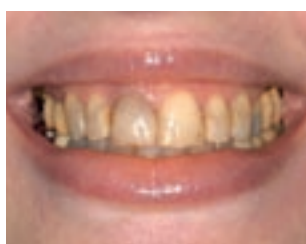

Fig. 1: Pre-operative smile view. Insufficient composite restorations on anterior teeth and PFM crowns on posterior teeth.

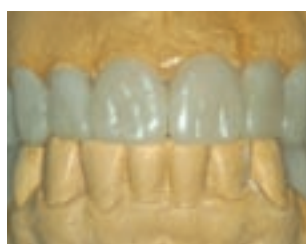

Fig. 2: Diagnostic wax-up of proposed treatment plan.

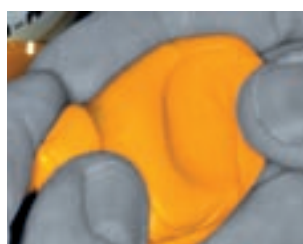

Fig. 3: Mixing of Express™ 2 Putty Soft VPS Material (3M ESPE) to impress wax-up.

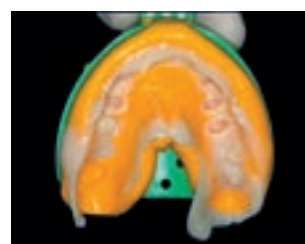

Fig. 4: Impression of the diagnostic wax-up of maxillary (Express™ 2 Putty Soft) filled with Protemp™ 4 Temporisation Material shade A2.

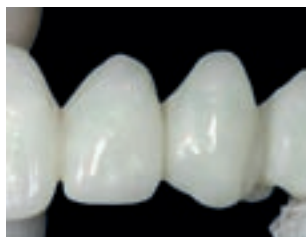

Fig. 5: Gauze with alcohol rubbed on the buccal surface after removal of excess on the margin.

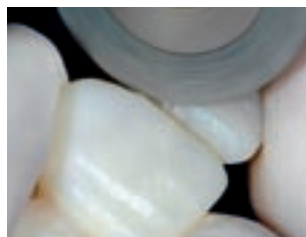

Fig. 6: Trimming in the interproximal area with a diamond disc.

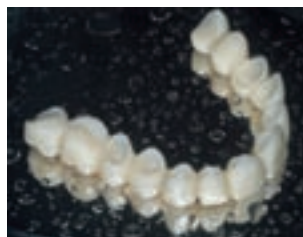

Fig. 7: Provisional restoration after excess removal.

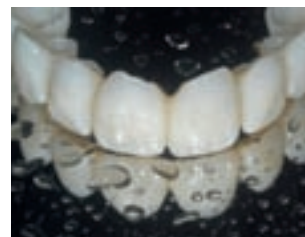

Fig. 8: Anterior view of provisional restoration after excess removal.

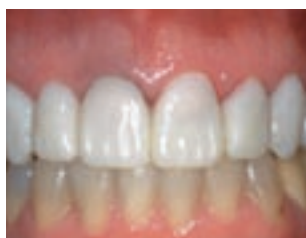

Fig. 9: Protemp™ 4 Temporary Restoration cemented with RelyX™ Temp NE Temporary Cement (3M ESPE).

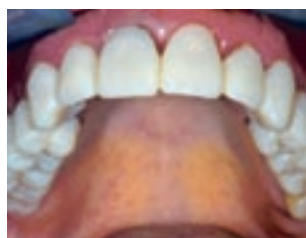

Fig. 10: Occlusal view of Protemp™ 4 Temporary Restoration after cementation.

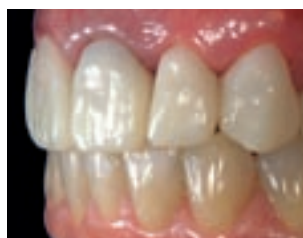

Fig. 11: Surface texture and marginal adaptation of provisional restoration.

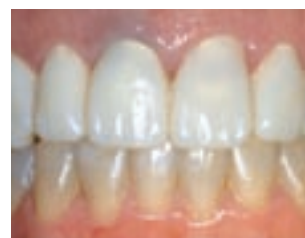

Fig. 12: Soft tissue response after 1 week. Due to the excellent marginal adaptation, healing is achieved in a few days.

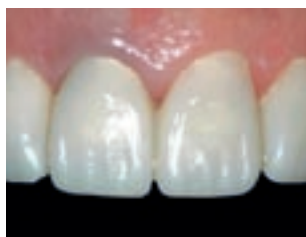

Fig. 13: Anterior view of soft tissue response after 1 week.

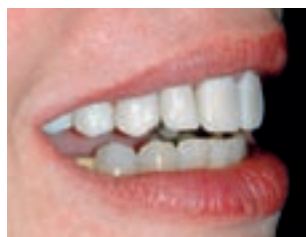

Fig. 14: Post-operative smile with Protemp™ 4 Temporaries.

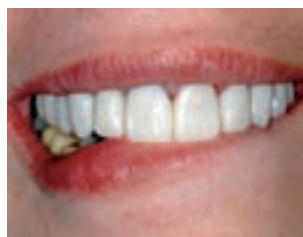

Fig. 15: Post-operative smile with temporaries in place.

Clinical case 2: Replacement of unaesthetic 4-unit anterior bridge

Clinical case by Dr. Olivier Etienne, Strasbourg, France
Lab work by Dental Laboratory D. Watzki, Illkirch, France

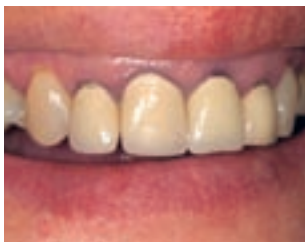

Fig. 1: Pre-operative view. Unpleasant aspect of the old restorations with recessed gingiva.

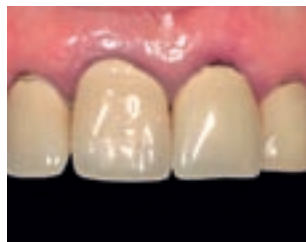

Fig. 2: Vestibular view of the upper incisors. Gingival problems demand replacing the four crowns.

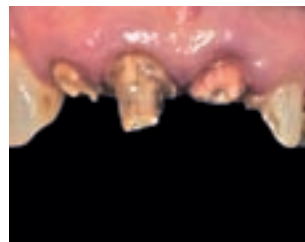

Fig. 3: Removal of the old crowns and new margin preparation.

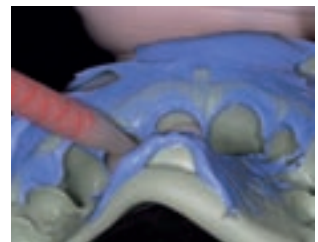


Fig. 4: The 1-step pre-operative impression technique provides an excellent matrix for fabricating aesthetic and accurate temporary restorations.

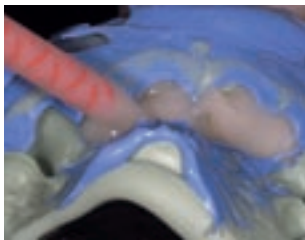


Fig. 5: Syringing the Protemp™ 4 Temporisation Material into the impression.

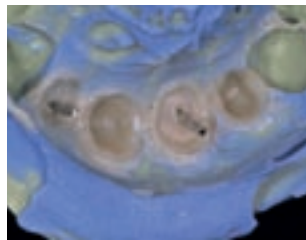


Fig. 6: Removing the matrix; the root pins that were inserted (but not cemented) into the root canal are now fixed within the temporary material.

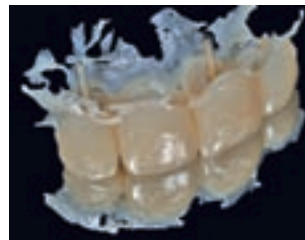


Fig. 7: After removing the 4-unit bridge from the matrix, the inhibition layer is cleaned with alcohol.

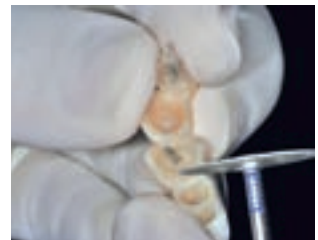

Fig. 8: Due to the accurate impression, few modifications need to be done. The teeth are still joined, but the embrasures are open.

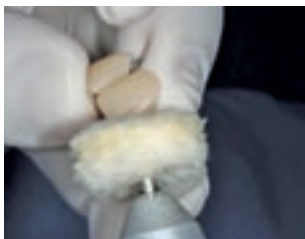

Fig. 9: Final polish.

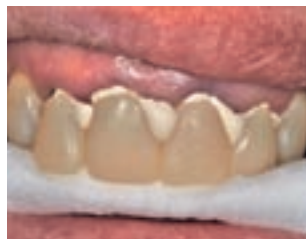

Fig. 10: Cementation of the temporary teeth using RelyX™ Temp NE Temporary Cement (3M ESPE).

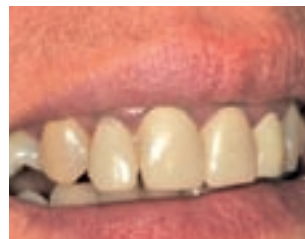

Fig. 11: Post-operative view: seated temporary restoration. The newly defined margins and the highly aesthetic qualities of Protemp™ 4 Temporisation Material are clearly visible.

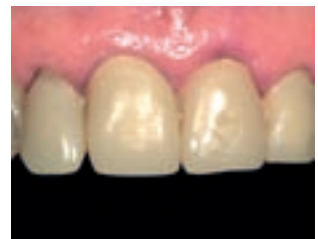

Fig. 12: The temporary restorations done by iso-technique are exactly the same shape and morphology of the pre-operative restorations.

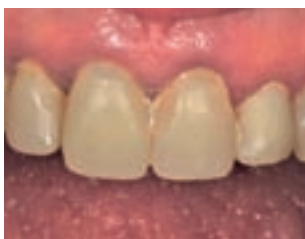

Fig. 13: Altering the shape of the Protemp™ 4 Temporary Restorations allows to simulate the appearance of the future final restoration.

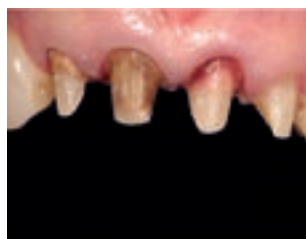

Fig. 14: During the second appointment, the root pins were cemented and the core build up completed. The tooth-coloured core build up material supports final aesthetics through its translucency.

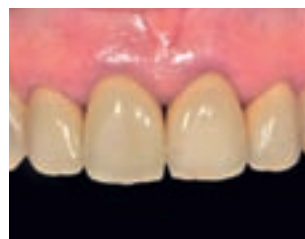

Fig. 15: Post-operative view. The final restorations blend perfectly into the patient's smile.

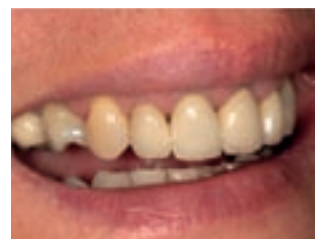

Fig. 16: Post-operative view of final restorations.

Clinical case 3: Improving function and aesthetics on upper central incisors

Clinical case by Dr. Joan Margarit Dalmau, Barcelona, Spain

Initial situation: 29 year-old male patient presented with two metal ceramic crowns on upper central incisors. Both teeth show gingival recession and are affected by severe endodontic problems. Both crowns had poor fit and low aesthetics.

Treatment plan: The endodontic treatment will be redone on both teeth. Additionally, the margins will be redefined to fulfill functional and aesthetic requirements. Protemp™ 4 Temporary Crowns will protect the teeth until seating of the final restorations.

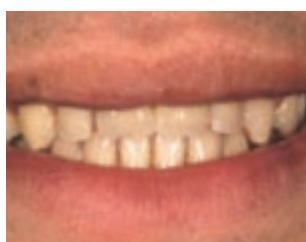

Fig. 1: Pre-operative view. Two insufficient single-unit crowns on teeth UR1 and UL1 with aesthetic and endodontic failures.

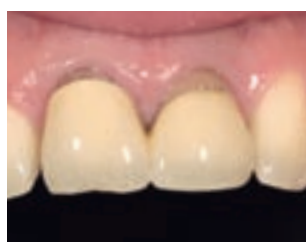

Fig. 2: Pre-operative view. The gingiva shows recession exposing the cervical area. Additionally, margin discolorations are present.

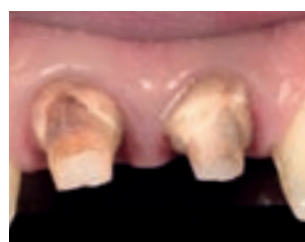

Fig. 3: Completed preparation.

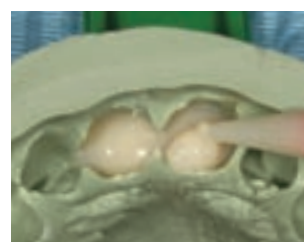

Fig. 4: Filling the preliminary impression (Express™ 2 Penta™ Putty VPS Material, 3M ESPE) with Protemp™ 4 Temporisation Material.

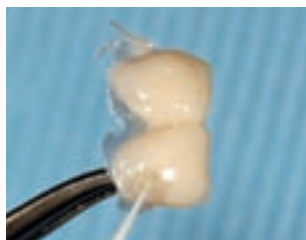

Fig. 5: Wiping off the inhibition layer with alcohol.

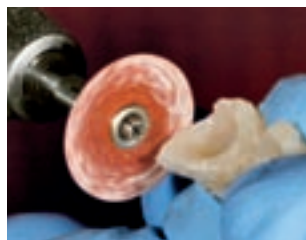

Fig. 6: Removing excess material and trimming the margins.

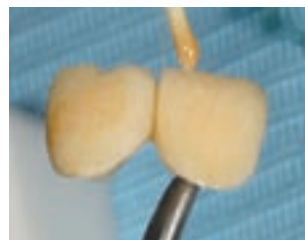

Fig. 7: Customisation: Using colours to optimally adapt to patient situation.

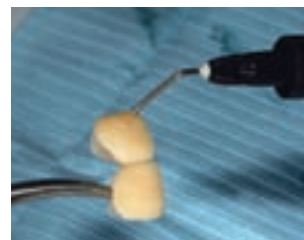

Fig. 8: Using Filtek™ Supreme XT Flowable Restorative to adapt the shape.

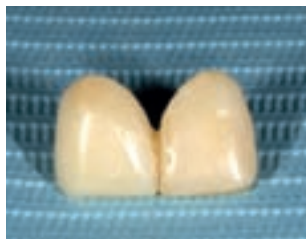

Fig. 9: Final Protemp™ 4 Temporary Restorations.

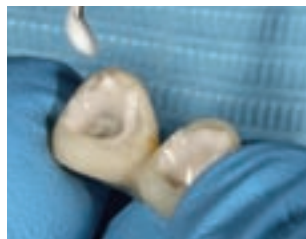

Fig. 10: Filling temporary cement into the temporary restorations.

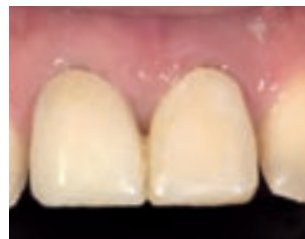

Fig. 11: Temporary restoration after cleaning off excess temporary cement.

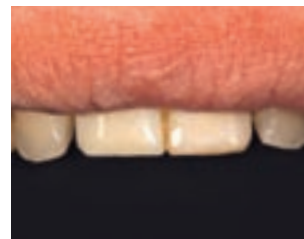

Fig. 12: Protemp™ 4 Temporary in place.

Clinical case 4: Replacement of failed anterior PFM crowns

Clinical case by Dr. Brent Fredrickson, St. Paul, Minnesota, USA

Initial situation: Patient presented with an upper removable partial denture and was not interested in a bridge. There is recurrent decay on teeth UR1 and UL1 and patient chose to have those two teeth replaced with all porcelain crowns.

Treatment plan: A treatment plan was formulated to replace existing PFM crowns on teeth UR1 and UL1 with all porcelain crowns.

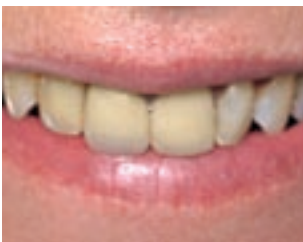

Fig. 1: Pre-operative view.

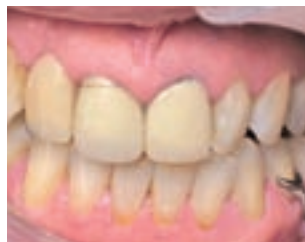

Fig. 2: Initial situation: recurrent decay on teeth UR1 and UL1 from existing failed PFM crowns.

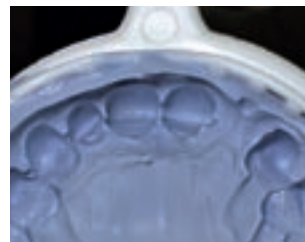


Fig. 3: Initial pre-operative impression.

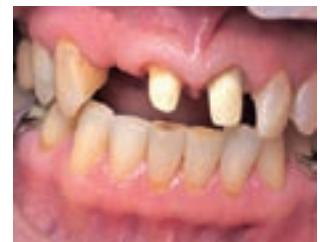

Fig. 4: Completed preparations for all ceramic crowns on teeth UR1 and UL1.

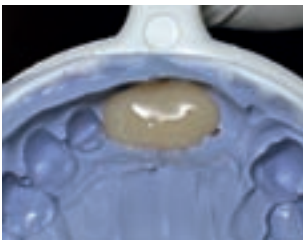


Fig. 5: Protemp™ 4 Temporisation Material filled into pre-operative impression.

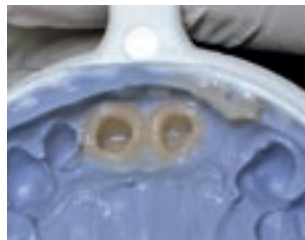


Fig. 6: Protemp™ 4 Temporisation Material and pre-operative impression removed from mouth.

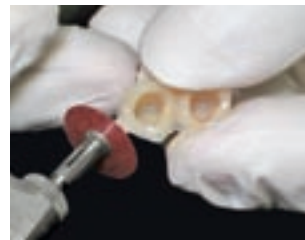

Fig. 7: Sof-Lex™ Disc (3M ESPE) used to trim excess material.

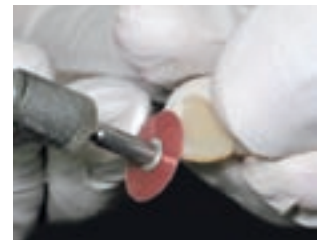

Fig. 8: Sof-Lex™ Disc (3M ESPE) used to refine margins.

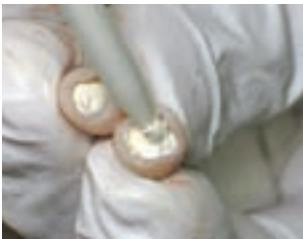

Fig. 9: Temporary cement placement.

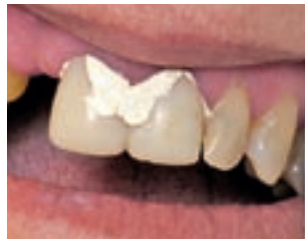

Fig. 10: Protemp™ 4 Temporaries seated with temporary cement.

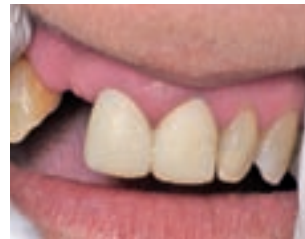

Fig. 11: Excess cement removed.

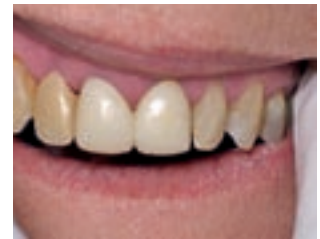

Fig. 12: Lightly polished and intra-oral adjustments made.

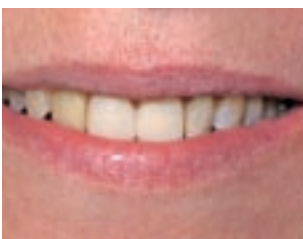

Fig. 13: Final Protemp™ 4 Temporaries.

Clinical case 5: Replacement of a dysfunctional and unaesthetic crown

Clinical case by Dr. Rakesh Jivan, Royal Leamington Spa, Warwickshire, UK

Initial situation: The patient presented with a complaint of poor aesthetics related to her existing maxillary right lateral PFM. The crown was monochromatic with gingival recession exposing metal margins. In addition, the tooth was much longer than both the UR3 and UR1.

Treatment plan: A treatment plan was formulated to replace the existing PFM with a Lava™ Zirconia Crown and restore the chipped central incisors using Filtek™ Supreme XT Universal Restorative at the incisal edges.

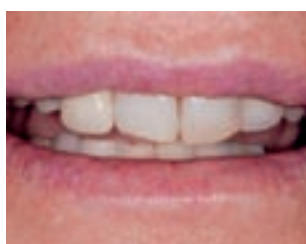

Fig. 1: Pre-operative view. Insufficient single-unit crown on tooth UR2.

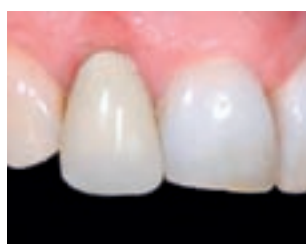

Fig. 2: Pre-operative view. The current crown (PFM) is monochromatic and extends beyond tooth UR1 and tooth UR3.

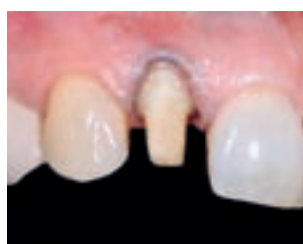

Fig. 3: Completed tooth preparation showing margin with gingival retraction in situ.




Fig. 4: Filling the pre-op impression (Position™ Penta™ VPS Alginate Replacement, 3M ESPE) with Protemp™ 4 Temporisation Material.

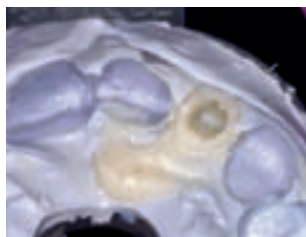


Fig. 5: The matrix with the temporary restoration removed from mouth. Wait for final setting.

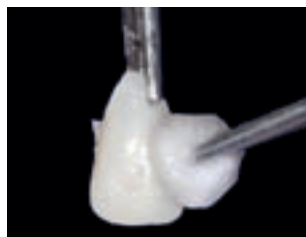


Fig. 6: Wiping the Protemp™ 4 Temporisation Material with alcohol to remove the inhibition layer is sufficient to get to the final surface.

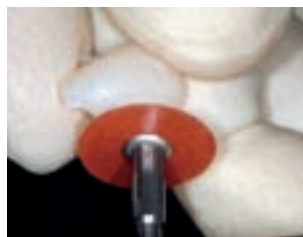

Fig. 7: Removing excess material at the margin.

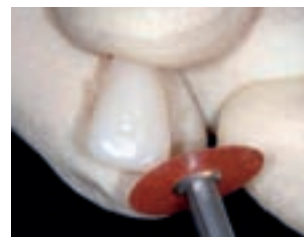

Fig. 8: Adjusting the occlusion.

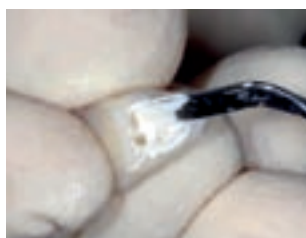

Fig. 9: Applying temporary cement.

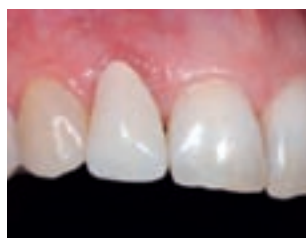

Fig. 10: Placement of the Protemp™ 4 Temporary Restoration with temporary cement.

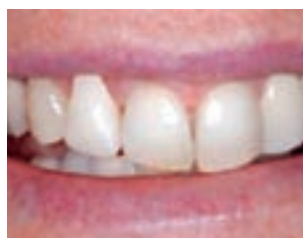

Fig. 11: Final temporary restoration in place.

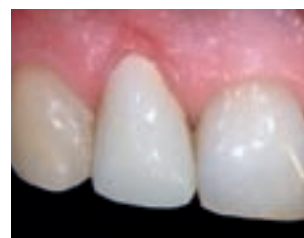

Fig. 12: Protemp™ 4 Temporary Restoration on tooth UR2 after 2 weeks wear time.

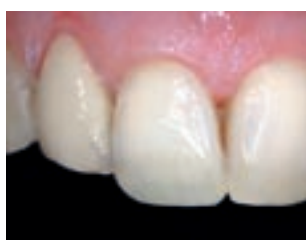

Fig. 13: Final Lava™ Zirconia Restoration on tooth UR2 and completed incisal Filtek™ Supreme XT Universal Restorative on teeth UR1 and UL1 (both 3M ESPE).

Clinical case 6: Replacing fractured and abraded upper central incisors

Clinical case by Dr. Joan Margarit Dalmau, Barcelona, Spain

Initial situation: 45 year-old male patient presented with both central upper incisors showing fractures and signs of abrasion.

Treatment plan: Both teeth will be prepared to receive zirconia full-ceramic crowns fulfilling the indicated functional and aesthetic requirements. An odontoplastia was performed on the lower incisors to provide adequate space for a good anterior guidance. With the Protemp™ 4 Temporisation Material features, it is easy to reshape the anatomy of these teeth on the temporary restorations.

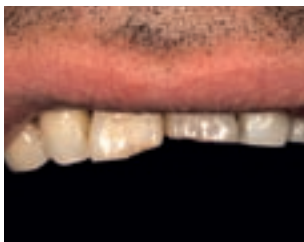

Fig. 1: Pre-operative view.

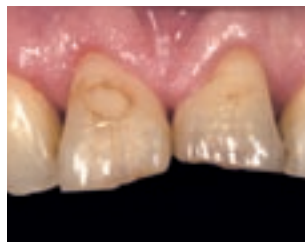

Fig. 2: Pre-operative view. Both upper incisors are fractured and abraded.

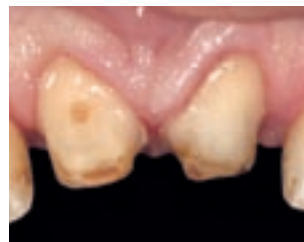

Fig. 3: Completed preparation.

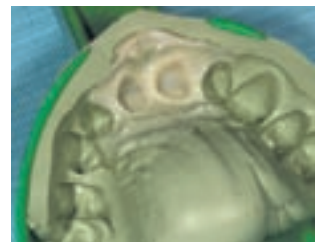

Fig. 4: Preliminary impression (Express™ 2 Penta™ Putty VPS Material, 3M ESPE) with Protemp™ 4 Temporisation Material after removing from the mouth.

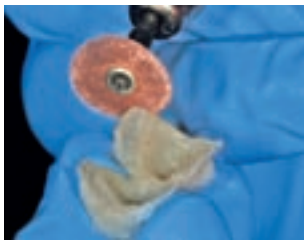


Fig. 5: Removing excess material around the margins.

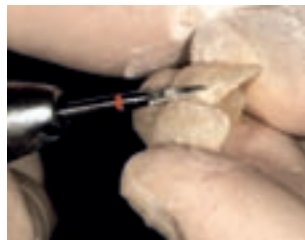

Fig. 6: Prepare temporary for application of colours to adapt to patient situation.

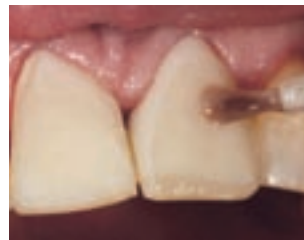

Fig. 7: Using colours for customisation.

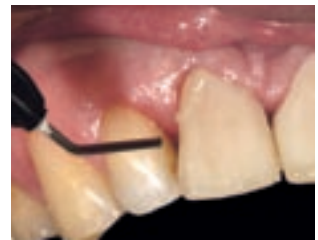

Fig. 8: Using Filtek™ Supreme XT Flowable Restorative to customise the shape.

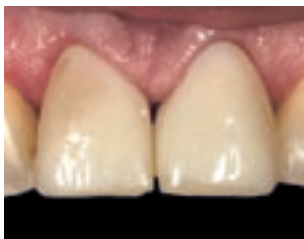

Fig. 9: Temporary restoration after temporary cementation.

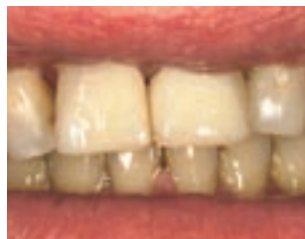

Fig. 10: Protemp™ 4 Temporaries in place.

Clinical case 7: Replacement of discolored anterior composite restoration

Clinical case by Dr. Paresh Shah, Winnipeg, Manitoba, Canada

Initial situation: 65 year-old female presented with a desire to have a more even and whiter smile. Her anterior teeth had large composite restorations that are discoloured and look “blotchy”.

Treatment plan: Due to the size of the existing restorations, Lava™ Zirconia Crowns were chosen for the anterior teeth. The patient also wished to replace teeth UR2 and UR3 with a fixed bridge (Lava™). Provisionals were fabricated with Protemp™ 4 Temporisation Material and were made from a diagnostic wax-up. Mounted casts and photographs of the final provisionals were used by the lab to fabricate the final Lava™ Zirconia Restorations.

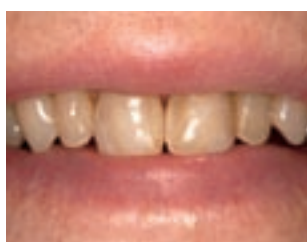

Fig. 1: Pre-operative view of patient's smile showing discoloured restorations.

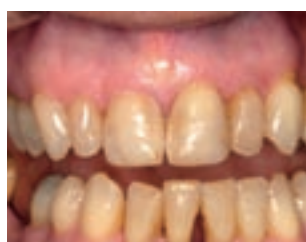

Fig. 2: Pre-operative view. Old discoloured restorations with uneven shading.

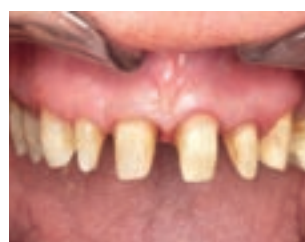

Fig. 3: View of the preparations for the Lava™ Restorations.

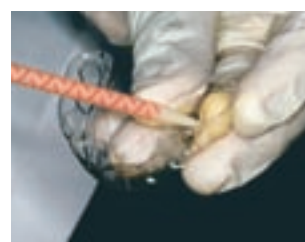


Fig. 4: Syringing of the Protemp™ 4 Temporisation Material into a vacuum form template which was created from a diagnostic wax-up prior to treatment.

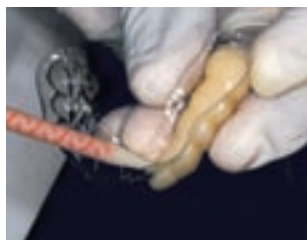

Fig. 5: The temporisation material is syringed into the entire template at once.

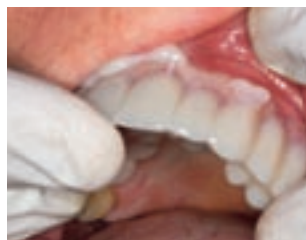

Fig. 6: Seating of template with Protemp™ 4 Temporisation Material over the preparations with excess expressed out.

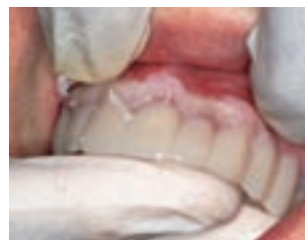

Fig. 7: Material is allowed to set for the recommended time intra-orally.

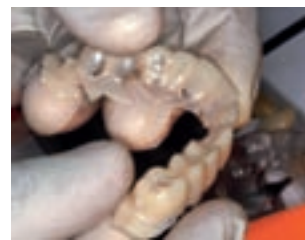

Fig. 8: Provisional is removed from the template in one piece and excess is trimmed carefully.

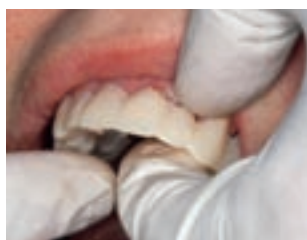

Fig. 9: Provisional is re-seated over the preparations in one piece, to check fit.

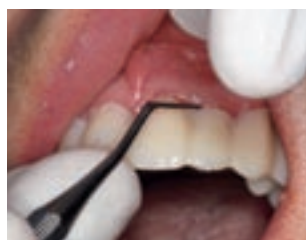

Fig. 10: Excess flash is carefully removed from the anterior region of the provisional.

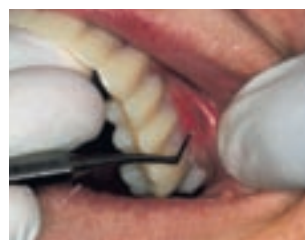

Fig. 11: Excess flash is carefully removed from the posterior region of the provisional.

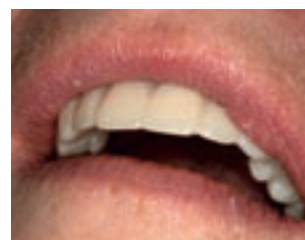

Fig. 12: Initial view of Protemp™ 4 Temporary Restoration after excess removal.

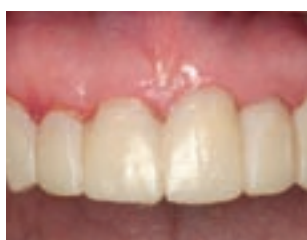

Fig. 13: View of Protemp™ 4 Temporaries after cementation with clear provisional cement.

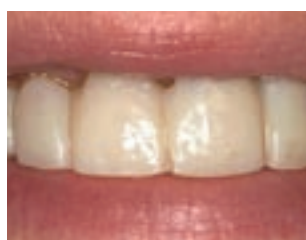

Fig. 14: View of provisionals after 5 days prior to any adjustments to length, shape and fabrication of the final restorations.

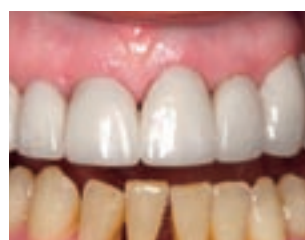

Fig. 15: Post treatment view of final Lava™ Zirconia Restorations immediately after cementation with RelyX™ Unicem Universal Resin Cement (both 3M ESPE).

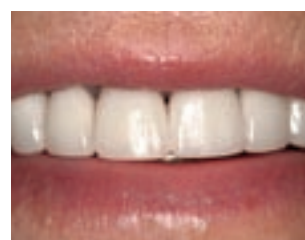

Fig. 16: Post treatment view of smile with final Lava™ Zirconia Restorations.

Clinical Case 8: Replacement of an insufficient PFM crown

Clinical Case by Dr. Rakesh Jivan, Royal Leamington Spa, Warwickshire, UK

Initial situation: The patient presented with a complaint of poor aesthetics related to her existing maxillary right central incisor PFM crown. The crown was monochromatic with gingival recession exposing metal margins. In addition, the crown margins had been leaking causing decay around the margins.

Treatment plan: A treatment plan was formulated to replace the existing PFM with a Lava™ Zirconia Crown.

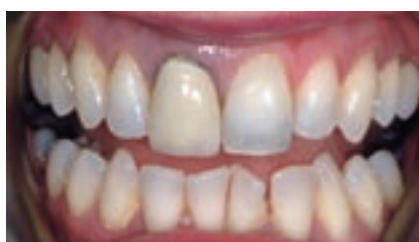

Fig. 1: Pre-operative view. Insufficient single-unit crown on tooth UR1 with exposed metal margins.

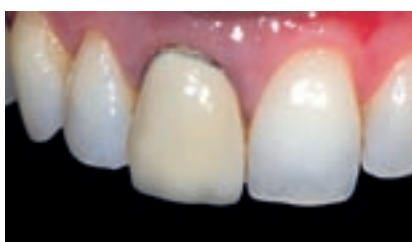

Fig. 2: Pre-operative view. The current crown (PFM) is monochromatic and shows very poor crown margins.

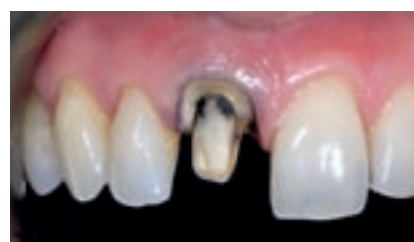

Fig. 3: Completed tooth preparation showing the margin with gingival retraction in situ. Note the discolouration of the tooth due to leakage around the PFM crown margins.

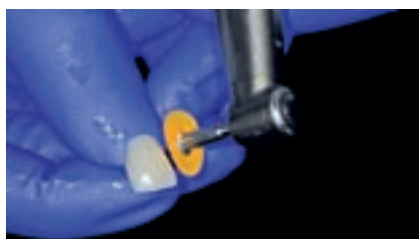

Fig. 5: Adjusting the occlusion and final polish.

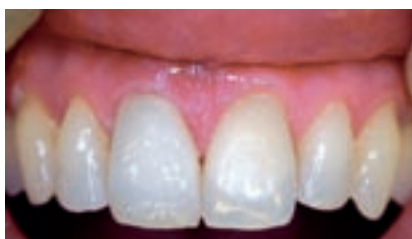

Fig. 6: Final view of Protemp™ 4 Temporary Crown.

Clinical case 9: Maxillary arch restoration

Clinical case by Dr. Carlos Sabrosa, Rio de Janeiro, Brazil

Initial situation: 44 year-old female patient presented with teeth UR2, UR7, UR8, UL7 and UL8 missing in the maxillary arch. Tooth UL3 had already been replaced with an implant. Provisional restorations over tooth UR3, with cantilever over tooth UR2, and over implant on tooth UL3. In the mandibular arch, teeth LL4, LL6, LL7, LL8, LR5, LR6 and LR8 are missing.

Treatment plan: After consultation with the patient, a decision was made to replace tooth UR2 with an implant. In the mandibular arch the patient will receive implants for teeth LL4, LL6 and LR6. Final restorations planned with all-ceramic single Lava™ Zirconia Crowns and a Lava™ Zirconia implant-supported fixed partial denture LL4-x-LL6.

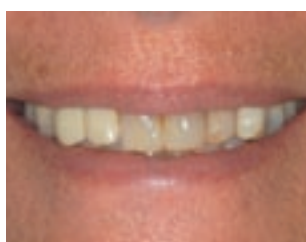

Fig. 1: Pre-operative smile view. Insufficient restorations on the anterior teeth and unpleasant smile.

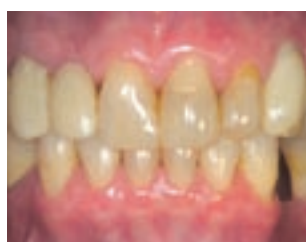

Fig. 2: Pre-operative intra-oral view. Insufficient composite restorations on the anterior teeth.



Fig. 3: Preliminary maxillary and mandibular impressions taken with Position™ Penta™ and Position™ Tray (both 3M ESPE) to fabricate diagnostic casts.

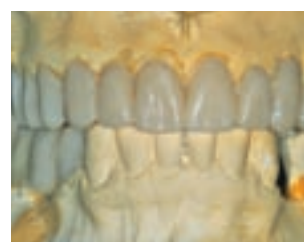

Fig. 4: Diagnostic wax-up of proposed treatment plan.

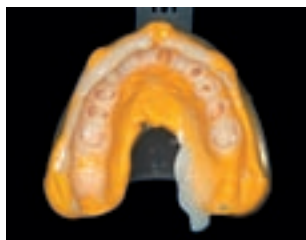

Fig. 5: Impression of the diagnostic wax-up (Express™ 2 Putty Soft VPS Material, 3M ESPE) filled with Protemp™ 4 Temporisation Material shade A2.

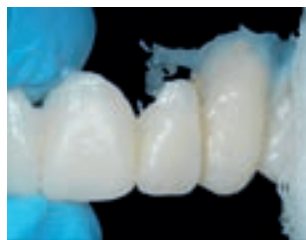

Fig. 6: Gauze with alcohol rubbed on the buccal surface.

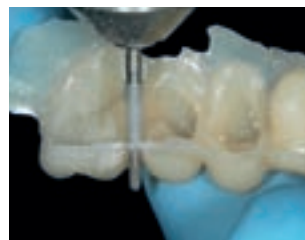

Fig. 7: Trimming of excess with high speed laboratory handpiece.

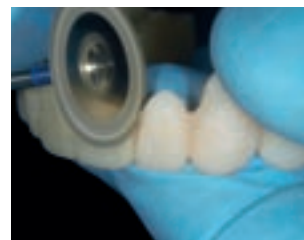

Fig. 8: Trimming in the interproximal area with a diamond disc.

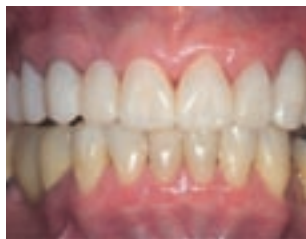

Fig. 9: Provisional restoration cemented with RelyX™ Temp NE Temporary Cement (3M ESPE). Screw-on provisional restoration on tooth UL3.

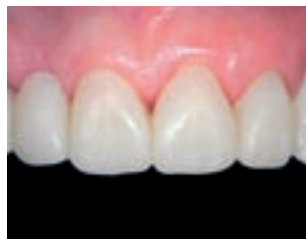

Fig. 10: Anterior view of provisional restoration cemented with RelyX™ Temp NE Temporary Cement (3M ESPE).

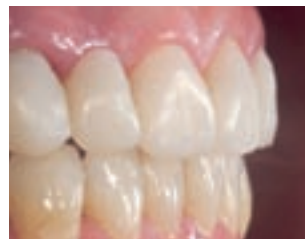

Fig. 11: Side view of Protemp™ 4 Temporary Restoration after cementation with RelyX™ Temp NE Temporary Cement (3M ESPE).

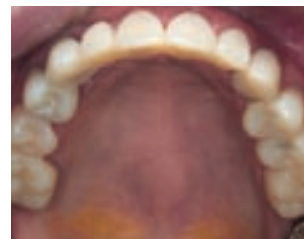

Fig. 12: Occlusal view of provisional restoration.

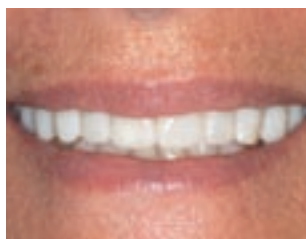

Fig. 13: Post-operative smile.

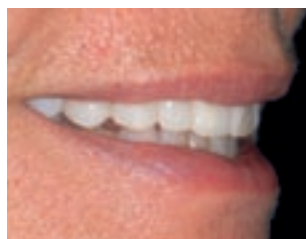

Fig. 14: Post-operative smile.

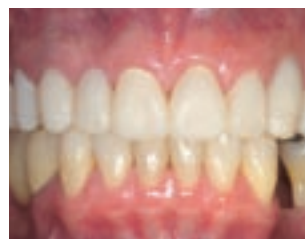

Fig. 15: Soft tissue response after 1 week. Due to the excellent marginal adaptation, healing is achieved within a few days.

Clinical case 10: Replacement of composite restorations with veneers

Clinical case by Dr. Suresh Nair, Malaysia

Initial situation: 36 year-old male patient with good gingival health presented with a desire for a nicer smile. There were some composite restorations on teeth UR1 and UL1.

Treatment plan: A treatment plan was formulated that included replacement of existing composites, placement of high aesthetic veneers for teeth UR5 to UL2, and placement of a bridge for teeth UL3 to UL5.

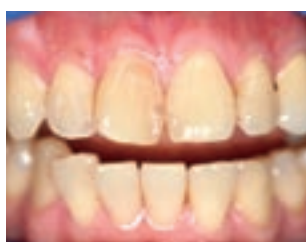

Fig. 1: Pre-operative view.

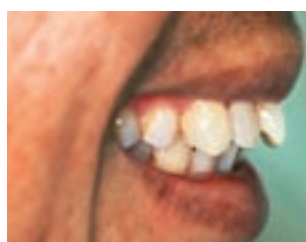

Fig. 2: Pre-operative, lateral view.

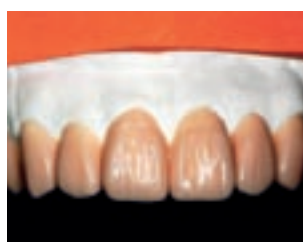

Fig. 3: Diagnostic wax-up.

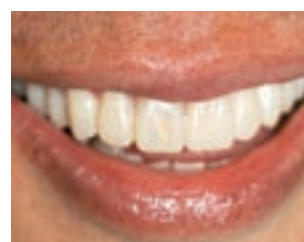

Fig. 4: Protemp™ 4 Temporary Veneers and Bridge in place without further polishing.

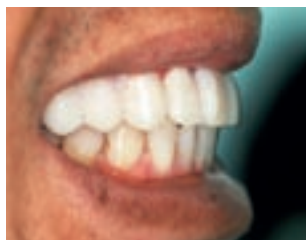

Fig. 5: Protemp™ 4 Temporary Veneers and Bridge in place, lateral view.

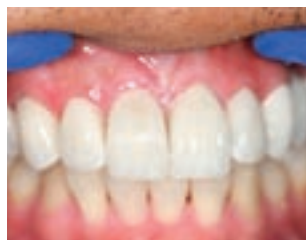

Fig. 6: Protemp™ 4 Veneers and Bridge cemented, not polished.

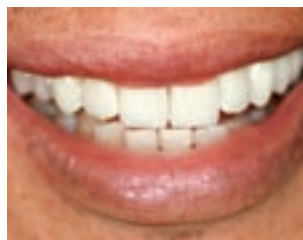

Fig. 7: Final temporary restoration.

Clinical case 11: Replacement of anterior restorations

Clinical case by Dr. Dennis Becker, Minden, Germany

Initial situation: Female patient presents after periodontitis treatment with a desire for more aesthetic anterior teeth. The upper anterior teeth appear elongated due to reduction of the gingiva. Teeth UR1, UR2 and UL1 are vital, but with large composite fillings. Margins of a PFM crown are exposed at teeth UL2 and UL3 which has been treated endodontically and has a composite build-up.

Treatment plan: After consultation with the patient, it was decided to have full-ceramic restorations. To save expense of long-term lab fabricated temporaries, it was decided to make a temporary restoration with Protemp™ 4 Temporisation Material prior to final Lava™ Zirconia Restoration.

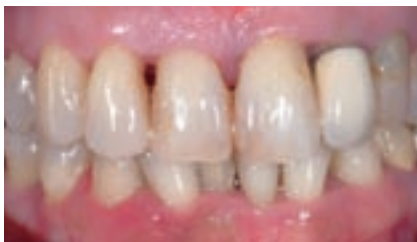

Fig. 1: Pre-operative view showing discoloured anterior teeth.

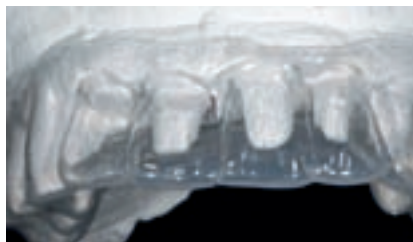

Fig. 2: Vacuum form template created from a diagnostic wax-up prior to treatment.

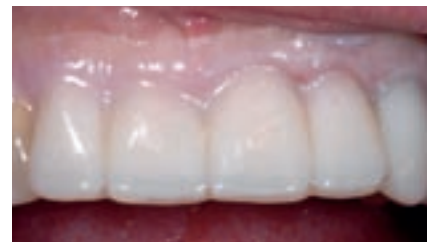

Fig. 3: Seating of template with Protemp™ 4 Temporisation Material.

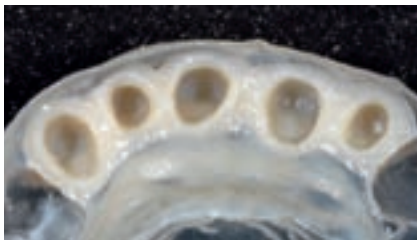

Fig. 5: Provisional is removed showing good impression detail.

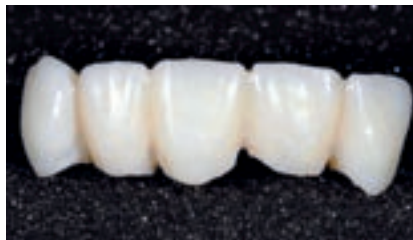

Fig. 6: View of completed temporaries.

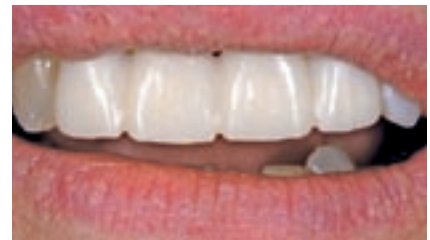

Fig. 6: View of Protemp™ 4 Temporaries after cementation.

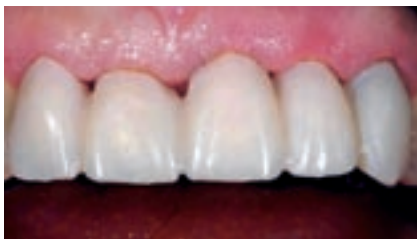

Fig. 5: View of Protemp™ 4 Temporaries after 14 days wearing time.

3M ESPE

3M ESPE AG
ESPE Platz
82229 Seefeld · Germany
E-Mail: info3mespe@mmm.com
Internet: www.3mespe.com

You + 3M ESPE =

Groundbreaking ideas for dentistry

3M, ESPE, Express, Filtek, Lava, Penta, Position, Protemp, RelyX and Sof-Lex are trademarks of 3M or 3M ESPE AG.

©3M 2009. All rights reserved.

01 (6.2009)