



1 DIAGNOSE

CLINICAL GUIDELINES

In accordance with the guidelines of the European Federation of Periodontology³, the **CLEAN&SEAL®** therapy follows after the patient has been instructed and motivated to maintain oral hygiene.

APPLICATION

Periodontitis or peri-implant infection > 5 mm probing depths associated with bleeding (BOP+).

2 CLEAN

CLEANING GEL

Mixing the two components results in an opaque, viscous gel of amino acids with 0,5 % sodium hypochlorite (A²H) and an alkaline pH which is gentle to the tissues.

INJECT A²H GEL

Start the mechanical debridement by injecting the cleaning gel into the sulcus. Let the gel act > 60 seconds before cleaning, for an optimum decontamination of the biofilm site and dissociation of granulated tissues.

3 REPEAT AT WILL

MECHANICAL CLEANING

After sufficient exposure to the cleaning gel, continue with the cleaning method of choice, such as titanium coated stainless steel micro-currettes, air-polishing or ultrasonic devices.



Do not rinse with CHX-containing products before, during and after treatment. (CHX = chlorhexidine)

4 SEAL

CROSSLINKED HYALURONIC ACID GEL

The gel consists of native as well as crosslinked hyaluronic acid. It needs to be applied into the pockets at room temperature even in the presence of blood and fluids.

INJECT xHyA GEL

After completion of the non-surgical debridement, the xHyA gel is applied into the site to prevent reinfection through its bacteriostatic property⁷. The hydrophilic property helps stabilize the blood clot.

5 HEAL

THE HEALING PROCESS

It is supported by the presence of hyaluronic acid which up-regulates several growth factors¹⁴ and therefore facilitates pocket reduction⁴.

PATIENT MAINTENANCE

Patient should refrain from brushing and eating for at least two hours after the application of the xHyA gel.

6 TREATMENT & RECALL PLAN

- ✓ **CLEAN&SEAL® PROCEDURE**
Apply according to protocol
- ✓ **RE-EVALUATION**
Week 1: Top-up the pocket with xHyA gel
- ✓ **RE-EVALUATION**
Week 3 & 6: Optional healing check
- ✓ **CHECK CLINICAL PARAMETERS**
Week 12: First check PD, CAL and BOP
- ✓ **MAINTENANCE**
Continuous: Maintain regular dental hygiene



CLEAN&SEAL®

LITERATURE

1. Page RC, Kornman KS. Periodontology 2000 1997; 14: 9–11.
2. Renvert S et al. J Clin Periodontol. 2006; 33: 362-369.
3. Sanz M et al. J Clin Periodontol. 2020; 47: 4–60.
4. Diehl D et al. Materials 2022, 15, 6508.
5. Jepsen S et al. J Clin Periodontol 2015;42(Suppl. 16):S152–S157.
6. Costa FO et al. Journal of Clinical Periodontology 2012;39:173– 183.
7. Pirnazar P et al. J Periodontol 1999;70:370–374.
8. Jurczyk K et al. Clin Oral Investig. 2016 Nov;20(8):2165-2173. Epub 2016 Jan 12
9. Rajan P et al. Universal Research Journal of Dentistry. 2013;3:113.
10. King SR et al. Surgery 1991;109(1):76-84.
11. Yildirim S et al. J Periodontol. 2017;15:1-14.
12. Pilloni A et al. Clin Oral Investig. 2018.
13. Mueller A et al. Clin Oral Investig. 2017;21(4):1013-1019.
14. Asparuhova M et al. J Periodontol Res 2019;54:33–45.
15. Asparuhova M et al. Clin Oral Investig. 2020;24(11):3923-3937.
16. Schmidlin PR et al. Clin Oral Investig. 2017
17. Radulescu V et al. Clin Oral Investig. 2022
18. Arvidson A.Thesis (ISBN: 91-628-5882), University of Gothenburg, Sweden. 2003.
19. Eliezer M, Clin O Inv 2019
20. Graves DT et al. (2011) J Oral Microbiol. 3.
21. Iorio-Siciliano V et al. Clin Oral Investig. 2021
22. Guarnelli ME et al. Minerva Stomatologia, 2015
23. Nobis et al. Materials 2022
24. Hussein et al. J Stomatol Oral Maxillofac Surg. 2023
25. Bach et al. Implants 2016

DOWNLOAD STUDIES



SCAN HERE



NON-SURGICAL PERIODONTAL AND PERI-IMPLANT THERAPY

CAN CURRENT CLINICAL RESULTS BE IMPROVED?

Unresolved problem

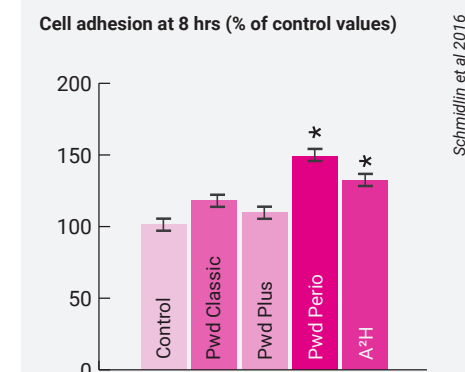
Despite careful post-operative oral hygiene protocols, deep periodontal and peri-implant pockets and inflammatory reactions may persist, leading to the resorption of tissues¹ and thus contributing to the risk of bone loss².



Current established non-surgical subgingival treatments might not show satisfying, long-lasting improvement of clinical parameters. In a recently published clinical study, the successful non-surgical treatment of deep persistent pockets with the **CLEAN&SEAL**® concept was presented showing rapid improvement of clinical parameters, so that invasive surgical intervention can be delayed or even completely avoided.^{4,19,22}

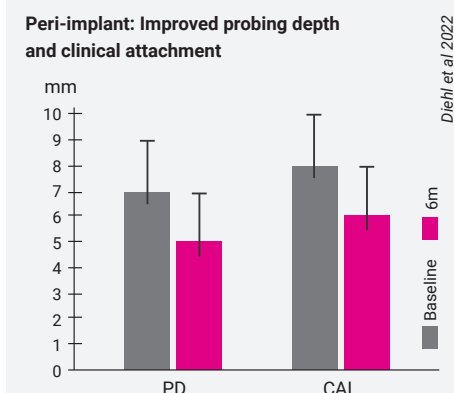
CLEAN&SEAL® reduces pockets after the first visit

A two step bio-film therapy that facilitates the decontamination of deep and persistent periodontal and peri-implant pockets and it also accelerates pocket healing.^{9-10,14}



CLEAN

An adjuvant cleaning gel (A²H) which contributes to the removal of the biofilm and dissociates granulation tissues from the healthy ones.



SEAL

The crosslinked hyaluronic acid gel (xHyA) which presents a slow resorption pattern, prevents reinfection and speeds up tissue healing.^{7,11,12}

SEAL

- Bacteriostatic properties protect the decontaminated wound for healing^{7,9}
- Speeding-up pocket closure through blood clot stabilization and growth factor attraction²⁰
- Adhesive gel, easy to apply especially in contact with blood
- Enhances soft and hard tissue cell adhesion and regeneration leading to pocket closure (PD) and better clinical attachment (CAL)^{4,9-15,19,21,22}

THE CLEAN&SEAL® CONCEPT



CLEAN

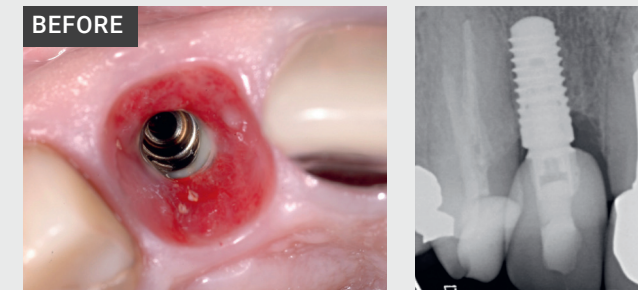
- Facilitates periodontal and peri-implant site decontamination¹⁷
- Breaks the biofilm matrix down and reduces the bacterial load¹¹
- Facilitates the separation of the granulated tissues from healthy tissues¹⁸
- With a 0.5% concentration of sodium hypochlorite, the A²H is gentle to the tissues, tooth- and implant surface and effective against the biofilm¹⁶
- In comparison to chlorhexidine, A²H reduces pocket depth (PD) and increases clinical attachment (CAL) to limit tissue recession¹⁷

PERI-IMPLANT REGENERATION

Clinical case provided by Dr T. Liechti, Switzerland

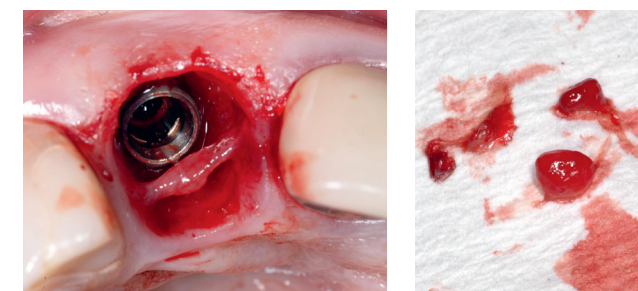
DIAGNOSE

7 mm deep pocket, BOP+, infected soft-tissues around an implant with pus after removal of the implant-crown.

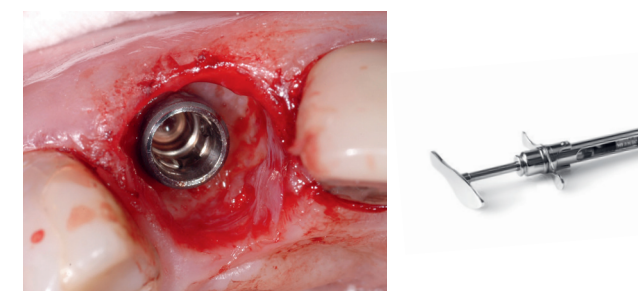


CLEAN&SEAL®

After several applications of the cleaning gel (A²H) the granulation tissues are separated from the healthy tissues and can be removed with a tweezer.

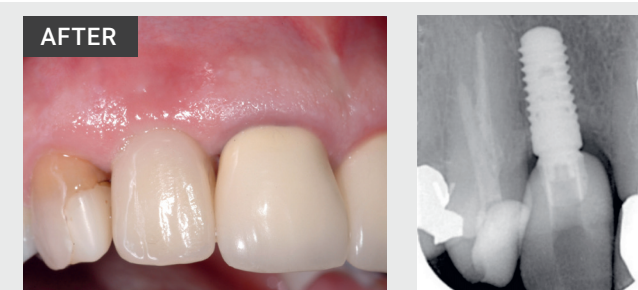

Initiate regeneration by filling the site with the crosslinked hyaluronic acid gel (xHyA).



FOLLOW-UP

6 months: Tight tissues, 5 mm pocket depth and with a visible increase in bone around the implant, show that the regeneration of both soft and hard tissues have progressed.

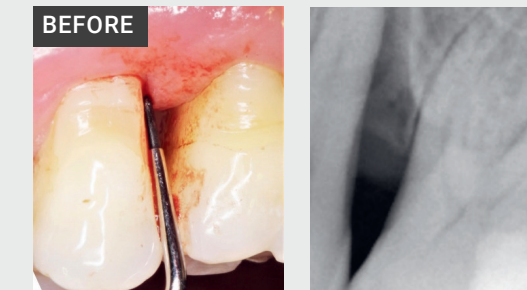

PERIODONTAL REGENERATION

Clinical case provided by Prof A. Friedmann, Germany

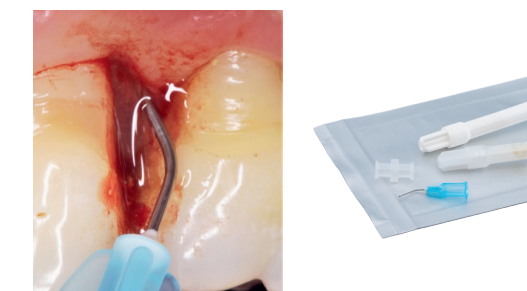
DIAGNOSE

Deep pocket distal to tooth 25 with PD of 8 mm and BOP+. The radiographic findings show the significant bone defect.

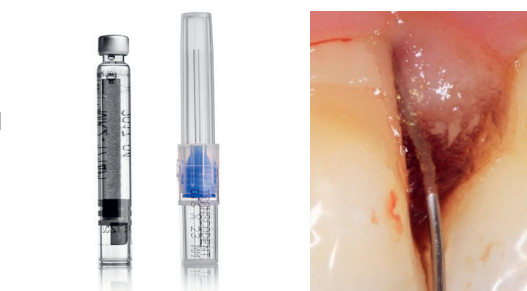

CLEAN&SEAL®

Biofilm removal through instrumentation and multiple applications of the cleaning gel.



After the non-surgical debridement, xHyA is applied to the pocket to seal the wound area and to promote the healing process.



FOLLOW-UP

5 months: Significant pocket reduction to 4-5 mm, stable inflammation-free situation (BOP-). The X-ray findings show an incipient bony filling.

